

Introduction

Split-skin grafting is used by surgeons to close skin defects following trauma, ulcers or deep burns. Although created under controlled, sterile conditions, DSWs can be a considerable burden during the healing process.

SpinCare™ creates on-the-spot, fully tailored nanofibrous dressing using electrospinning technology, for any wound shape and contour; mimicking the extracellular matrix serving as an excellent medium for tissue repair and healing.

Patient History

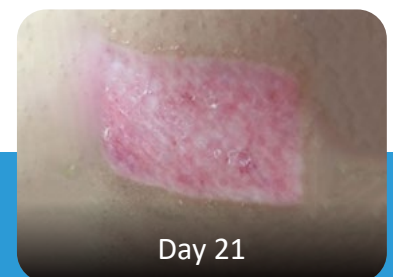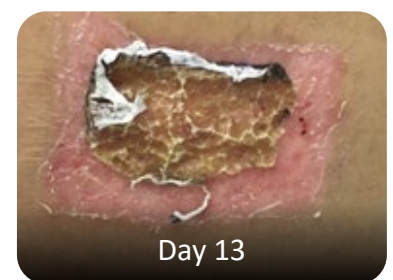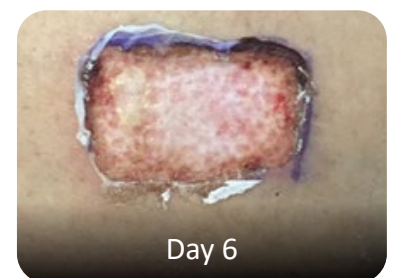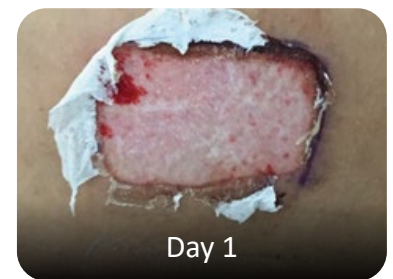
MH, 27 year old female with no previous medical history arrived to the emergency room with multiple skin abrasions on the extremities after a motorcycle accident (7% TBSA). The patient showed skin avulsion on the left foot requiring skin graft transplantation.

Treatment

A skin graft of 15 cm² in area and 0.3 mm depth was harvested from the left thigh. The donor site wound was treated with epinephrine-soaked gauze in preparation for dressing. SpinCare™ was applied resulting within minutes in a white nanofibrous dressing with excellent coverage and full adherence to wound geometry. A secondary dressing was applied to absorb excess exudates.

Case Results

The SpinCare™ dressing was left on the wound until peeled off on its own when the tissue underneath epithelialized. Dressing transparency allowed wound evaluation without removal. No complaints of pain were recorded. No evidence for infection found. Patient follow up will continue for 12 months.



Conclusions

Using the SpinCare™ dressing was safe and effective, demonstrating a good healing process. The SpinCare™ dressing behaved like a temporary skin and supported wound epithelialization underneath the dressing within 14 days.